



PATIENT

Leroy Tonelli

SPECIES

Feline

BREED

DSH

SEX

Male Neutered

AGE

4 years

WEIGHT

9.7lbs

INTERPRETED BY

Maggie Machen
Lamy, DVM
DACVIM (Cardiology)

PRESENTING CLINICAL SIGNS

History: Leroy is referred for a heart murmur noted in March. He is doing well at home with no clinical issues. Good appetite; normal activity level. On exam: NSR, grade III/VI parasternal murmur, PSS, lung fields clear, compressible thorax. BP after sedation: 100mmHg. *Sedated with propofol for study.

ECHOCARDIOGRAM FINDINGS

2D, m-mode, color flow and Doppler imaging is available.

Left ventricle: The LV diameter is normal with adequate myocardial function. The LV wall thicknesses are normal. There is a diffusely hyperechoic endocardium consistent with mild fibrosis. The endocardium appears remodeled.

The papillary muscles are hypertrophied; tertiary muscle visualized.

Left atrium: The left atrium is moderately increased in dimension. No smoke or thrombi visualized.

Mitral valve: Bi leaflet thickening and elongation with abnormal closure. No obvious stenosis. The tip of the mitral valve is visible in the LVOT during systole. Moderate eccentric mitral regurgitation is noted secondary to SAM.

Aortic valve/Aorta: The aortic valve is normal in morphology and mobility. Aortic outflow velocities are moderate to severely elevated with a dynamic profile. No aortic insufficiency.

Right ventricle: Normal right ventricular diameter and morphology indicating no overt evidence of pulmonary arterial hypertension.

Right atrium: The right atrium is normal in dimension.

Tricuspid valve: The tricuspid valve appears normal with no tricuspid regurgitation.

Pulmonary valve/Pulmonary artery: The pulmonic valve is normal in morphology and mobility. No pulmonic insufficiency. Mildly elevated RVOT velocity with a dynamic component.

Pericardium/other: No pericardial or pleural effusion noted. No obvious cardiac masses.

Heart rhythm: ECG reveals a sinus rhythm with an average HR of 130bpm.

IMAGING

PERFORMED BY

Pamela Harrigan,
RDCS

HOSPITAL NAME

Mass Veterinary
Services

REFERRING VET

Dr. Masloski

INVOICE

25401

DATE

7/19/22

2-Dimensional Measurements

Ao diam (cm)	0.9
LA diam (cm)	1.5
LA:Ao (Swe)	1.7
IVS thickness (cm)	0.42
LVID diastole (cm)	1.4
PW thickness (cm)	0.55
LVID systole (cm)	0.6
FS (%)	57

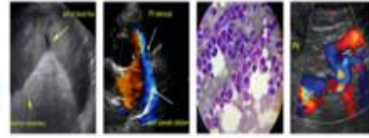
Doppler Measurements

PV Vmax (m/s)	0.52
AoV Vmax (m/s)	4.5
MR Vmax (m/s)	NM
TR Vmax (m/s)	NA
TR PG (mmHg)	NA

INTERPRETATION OF THE FINDINGS

The diagnosis and cause of the murmur is mitral valve dysplasia leading to an obstructive LVOT flow pattern and moderate MR. What is unusual is there is no significant LV hypertrophy present. Regardless, there is moderate left atrial dilation, indicating the risk for progression to spontaneous CHF and/or a thrombotic event is elevated going forward. No additional issues are identified.

Long term prognosis is guarded given the age of the patient and highly variable nature of asymptomatic feline heart disease. Many cats will remain asymptomatic until mid-life or



PATIENT
Leroy Tonelli

beyond, while others develop CHF within the first years. Close monitoring for progression of LA dilation in the future will help determine long term prognosis.

SPECIES
Feline

While no medications have been shown to definitively alter long term outcome at this stage of disease, atenolol is often initiated to decrease the outflow obstruction. In cases of solely primary MV dysplasia this can lead to improvement in the degree of obstruction and hypertrophy. Given a lack of significant LV hypertrophy it is unknown how beneficial this medication will be; however, it is reasonable to attempt to relieve the obstruction going forward. Additionally, an anticoagulant could be argued with this degree of atrial dilation, however this medication can be very difficult to administer.

BREED
DSH

RECOMMENDATIONS

SEX
Male Neutered

- Administer titrating dose of atenolol: 25mg tablets; Give ¼ tab once daily. Recheck heart rate in 1-2 weeks with target stressed rate of 140-160bpm 12-24 hours post-administration. Increase as needed until target reached.
- If elected/possible, administer Clopidogrel (Plavix) 75mg tabs, give ¼ tab PO q24 h (NOTE: This medication is very bitter along the cut edge and may cause oral foaming).
- Elective anesthesia is not advised until response to atenolol is evaluated.
- Monitor for any clinical evidence of cardiac compromise, including respiratory changes and/or signs of a blood clot event (paralysis, neurologic changes, etc.).

AGE
4 years

WEIGHT
9.7lbs

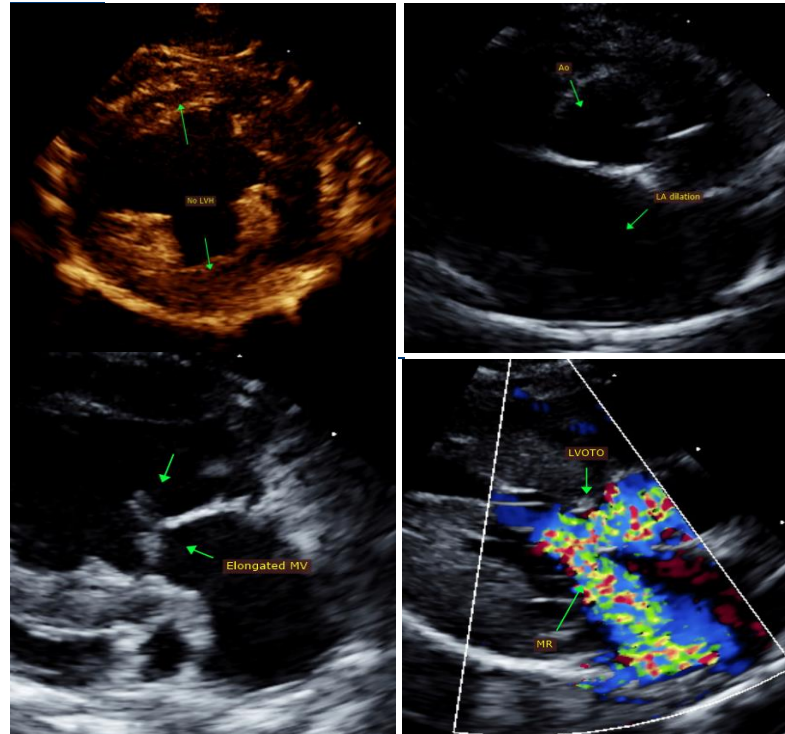
PLAN

- Recommend recheck echocardiogram in six months to assess for progression, sooner if clinical signs arise in the interim.

INTERPRETED BY

Maggie Machen
Lamy, DVM
DACVIM (Cardiology)

IMAGES



IMAGING PERFORMED BY

Pamela Harrigan,
RDCS

HOSPITAL NAME

Mass Veterinary Services

REFERRING VET

Dr. Masloski

INVOICE

25401

DATE

7/19/22



PATIENT

Leroy Tonelli

The information and recommendations provided are based on the images presented by the referring veterinarian. No evaluation can be communicated regarding pathology that was not visible in the image/video clips provided.

SPECIES

Feline

Thank you for this referral. This report was generated using transcription software, and minor dictation errors may be present. If the clinical or image interpretation does not parallel your findings or if I can be of any further assistance, please contact me.

BREED

DSH

Maggie Machen Lamy, DVM
Diplomate of the American College of Veterinary Internal Medicine (Cardiology)
info@sonopath.com

SEX

Male Neutered

Echocardiogram performed by: Pamela Harrigan, RDCS
Pet Animal Ultrasound Service (4paus.com)

AGE

4 years

WEIGHT

9.7lbs

INTERPRETED BY

Maggie Machen
Lamy, DVM
DACVIM (Cardiology)

**IMAGING
PERFORMED BY**

Pamela Harrigan,
RDCS

HOSPITAL NAME

Mass Veterinary
Services

REFERRING VET

Dr. Masloski

INVOICE

25401

DATE

7/19/22